

Correspondence

Variant palmaris profundus enclosed by an unusual loop of the median nerve

According to the usual description in most anatomy texts, the median nerve in the forearm passes between the 2 heads of pronator teres. It continues distally between flexor digitorum superficialis and profundus almost to the retinaculum. Muscular branches leave the nerve near the elbow and supply all superficial muscles of the anterior part of the forearm except flexor carpi ulnaris. Many variations of the median nerve in the forearm have been reported (Urban & Krosman, 1992). The palmaris profundus is also a rare anomaly of the forearm (Dyreby & Engber, 1982). It originates from the radial side of the common flexor tendon in the proximal forearm and inserts into the undersurface of the palmar aponeurosis. The origin of palmaris profundus may be close to the median nerve and its branches, and may be involved in compressive neuropathy of the anterior interosseous nerve. Its tendon crossing through the carpal canal has been implicated in the carpal tunnel syndrome (reviewed by Lahey & Aulicino, 1986). In some cases, palmaris profundus was found enclosed in a common fascial sheath with the median nerve (Stark, 1992; Sahinoglu et al. 1994). To indicate its close association with the median nerve, the palmaris profundus was also named 'musculus comitans nervi mediani' (Sahinoglu et al. 1994). This article reports an unusual loop of the median nerve encircling an anomalous palmaris profundus in the forearm, which, to the best of our knowledge, has not been previously described.

The present study was conducted on both upper limbs of a male cadaver. The anomalies reported here were found during routine dissection in the Department of Anatomy, Taipei Medical College. Palmaris profundus was dissected in the forearm, and its course, origin, and relation with the median nerve were noted.

During the dissection, the left forearm showed the usual structures, including a normal palmaris longus in both limbs. In the right forearm, an unusual median nerve and a rare anomaly, a palmaris profundus, were found. The anomalous palmaris profundus muscle originated from the ulnar epimysium of pollicis longus in the proximal quarter of the forearm. The muscle belly which was 6 cm in length split the median nerve near the junction of the middle and proximal thirds of the forearm. After crossing the medial root of the median nerve, the muscle belly was reduced into a tendon. The latter initially coursed deep to the median nerve, then lay on the radial side of the nerve before transversing the carpal canal (Fig. 1). Distally, the tendon fanned out to insert on the deep surface of both the flexor retinaculum and the palmar aponeurosis. At the origin of palmaris profundus, the median nerve split into 2 roots to enclose the muscle belly. Each root was equal and was about 5 cm in length (Figs 1, 2). A branch of the median nerve arising from the trunk immediately before the division of the nerve innervated palmaris profundus (Fig. 2). Except for the 2 abovementioned anomalies, the anatomy of the ulnar nerve, the anterior interosseous nerve and the final distribution of the median nerve showed the usual pattern. This was also true for the arterial framework in the forearm with the absence of the median artery.

The palmaris profundus has been thought to be a substitute structure for an absent palmaris longus or actually to represent palmaris longus with an aberrant distal course (Reimann et al. 1944). Dyreby & Engber (1982) reported a case of bilateral carpal tunnel syndrome with a unilateral palmaris profundus coexisting with a normal palmaris longus in the right hand, and Floyd et al. (1990) reported a case of bilateral palmaris profundus and palmaris longus. As a result, palmaris profundus may also be an accessory muscle in addition to representing merely an anatomical variation or a substitute structure for the palmaris longus, as noted by Reimann et al. (1944). The occurrence of an anomalous palmaris profundus muscle is very rare. Most were found when operating at the wrist for neurological symptoms. The origin of palmaris profundus was therefore not identified in the intraoperative findings (Dyreby & Engber, 1982; Floyd et al. 1990; Bauer & Trusell, 1992; Server et al. 1995), since proximal dissection was not indicated clinically when the patients declined further diagnostic analysis or surgical intervention. In general, palmaris profundus arises from the fibrous tissue of the proximal third of the volar radial forearm (see review by Lahey & Aulicino, 1986). Descriptions of the origin of this anomaly have been based on only a few cadaveric dissections (Reimann et al. 1944). In our cadaveric dissection, we found that the palmaris profundus originated from the ulnar epimysium of flexor pollicis longus in the proximal fourth of the forearm, indicating the variable origin of the anomaly. It is also true for the variability of palmaris profundus at the wrist. In previous reports, the tendon of palmaris profundus was found lying on the palmar-ulnar surface of the median nerve throughout the carpal canal and inserting distally into the undersurface of the palmar aponeurosis (Dyreby & Engber, 1982; Floyd et al. 1990; Stark, 1992; Server et al. 1995). In our case, the palmaris profundus tendon coursed radial to the median nerve at the entrance of the carpal tunnel. Distally, it spread out to attach to the deep surface of both the flexor retinaculum and the palmar aponeurosis. The present dissection revealed the origin of flexor pollicis longus from the ulnar epimysium and its position palmar radial to the median nerve which differ from previous descriptions for palmaris profundus.

Stark (1992) and Sahinoglu et al. (1994) reported 3 cases of palmaris profundus that was enclosed within the investing tissues surrounding the median nerve. The unusual muscle had been named 'musculus comitans nervi mediani' by Sahinoglu et al. (1994) to signify its close and important relationship to the median nerve. Being an intimate travelling companion of the median nerve through the forearm and into the hand, this was also found in the present case. As observed in the dissection, the muscle belly of palmaris profundus split the median nerve in the forearm, the nerve forming a loop in the proximal third of the forearm. The median nerve forming a ring enclosing the median artery has been described by several authors (Srivastava & Pande, 1990; Sañudo et al. 1994).

The anomalous palmaris profundus in association with

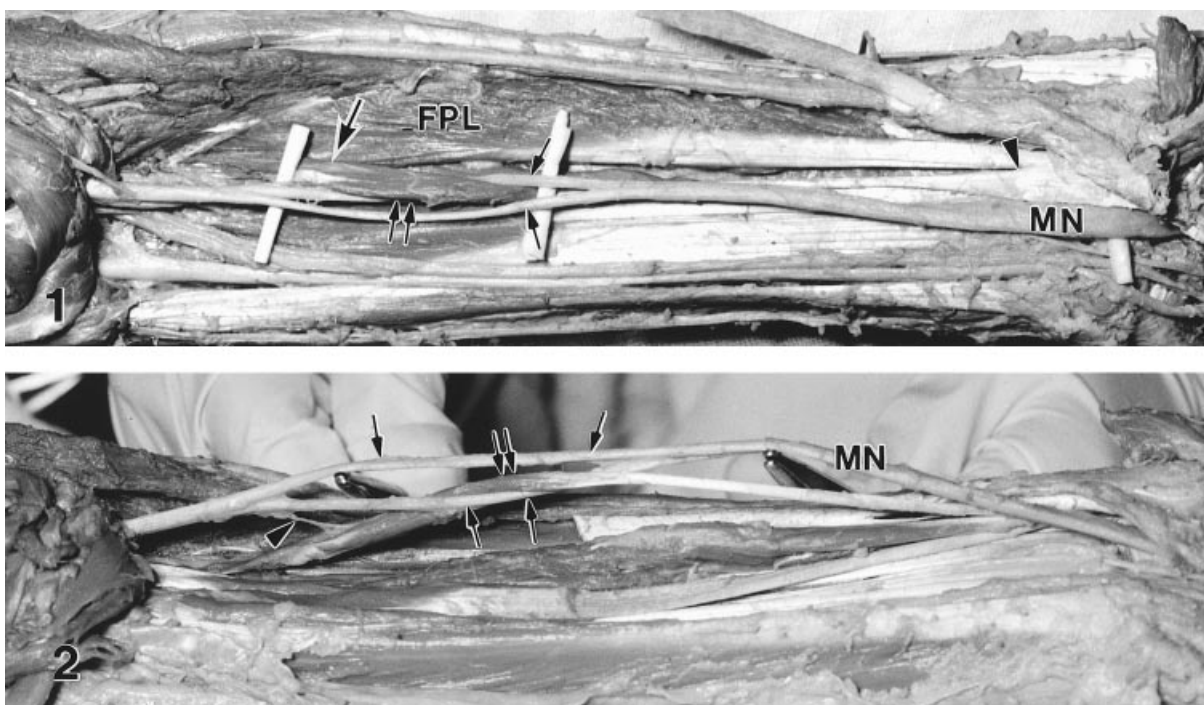


Fig. 1. Ventral view of a variant palmaris profundus in a right embalmed forearm. Note the origin (large arrow) of this anomalous muscle from the ulnar epimysium of flexor pollicis longus (FPL) and its fan-like, distal tendon (arrowhead) lying radial to the median nerve (MN). The muscle belly (double arrows) of the variant splits the median nerve into 2 roots (small arrows).

Fig. 2. Ulnar view of a variant palmaris profundus in a right embalmed forearm. The median nerve (MN), lifted up by forceps, forms a ring (arrows) enclosing the muscle belly (double arrows) of palmaris profundus. Note that the variant is innervated by a branch of the median nerve (arrowhead).

median nerve compression at the wrist has been implicated in the carpal tunnel syndrome (Dyrebey & Engber, 1982; see review by Lahey & Aulicino, 1986; also Floyd et al. 1990; Bauer & Trusell, 1992; Server et al. 1995). However, Stark (1992) stated that the palmaris profundus muscle was not necessarily always the cause of the carpal tunnel syndrome in such instances. Although the median nerve was found to be intimately related to palmaris profundus at the wrist in the present case, we do not know if this anomaly gave rise to the carpal tunnel syndrome since the clinical history was not available in this cadaveric study. As reviewed by Lahey & Aulicino (1986), the location of the origin of palmaris profundus made it a possible cause of anterior interosseous nerve paralysis (Spinner, 1978). In our case, such as unusual division of the median nerve by the muscle belly of palmaris profundus might give rise to a compressive neuropathy as a result of contraction of the associated muscle.

HSIU-CHU CHOU¹, HELLEN JENG¹, TSUI-LING KO¹,
MAN-HUI PAI¹, CHIU-YUN CHANG¹, AND
CHING-HSIANG WU^{2*}

¹ Department of Anatomy, Taipei Medical College
, and

² Department of Biology and Anatomy, National Defense
Medical Center, Taipei, Taiwan

Corresponding author.

REFERENCES

- BAUER JM, TRUSELL JJ (1992) Palmaris profundus causing carpal tunnel syndrome. *Orthopedics* **15**, 1348–1349; discussion 1349–1350.
- DYREBY JR, ENGBER WD (1982) Palmaris profundus – rare anomalous muscle. *Journal of Hand Surgery – American Volume* **7**, 513–514.
- FLOYD T, BURGER RS, SCIARONI CA (1990) Bilateral palmaris profundus causing bilateral carpal tunnel syndrome. *Journal of Hand Surgery – American Volume* **15**, 364–366.
- LAHEY MD, AULICINO PL (1986) Anomalous muscles associated with compression neuropathies. *Orthopaedic Review* **15**, 199–208.
- REIMANN AF, DASELER EH, ANSON BJ, BEATON LE (1944) The palmaris longus muscle and tendon. A study of 1,600 extremities. *Anatomical Record* **89**, 495–505.
- SAHINOGLU K, CASSELL MD, MIYAUCHI R, BERGMAN RA (1994) Musculus comitans nervi mediani (M. palmaris profundus). *Anatomischer Anzeiger* **176**, 229–232.
- SAÑUDO JR, CHIKWE J, EVANS SE (1994) Anomalous median nerve associated with persistent median artery. *Journal of Anatomy* **185**, 447–451.
- SERVER F, MIRALLES RC, GALCERA DC (1995) Carpal tunnel syndrome caused by an anomalous palmaris profundus tendon. *Journal of Anatomy* **187**, 247–248.
- SPINNER M (1978) *Injuries to the Major Branches of Peripheral Nerves of the Forearm*, 2nd edn, p. 192. Philadelphia: WB Saunders.
- SRIVASTAVA SK, PANDE BS (1990) Anomalous pattern of median artery in the forearm of Indians. *Acta Anatomica* **138**, 193–194.
- STARK RH (1992) Bilateral palmaris profundus causing bilateral carpal tunnel syndrome. *Journal of Hand Surgery – American Volume* **17**, 182–183.
- URBAN T, KROSMAN M (1992) Variation of the median nerve in the forearm and the wrist. *Folia Morphologica (Warszawa)* **51**, 77–79.